



## Research article

## EXPRESSION OF TOLL-LIKE RECEPTOR 2 AND TOLL-LIKE RECEPTOR 4 IN CHRONIC PERIODONTITIS BY INDIRECT IMMUNOFLUORESCENCE

\* MRS D'SOUZA ROMALDIN S<sup>1</sup>, BHAT KISHORE G<sup>2</sup>, NAYAK RAMAKANT<sup>3</sup>, D. SAILAJA<sup>4</sup>

## AUTHOR DETAILS

<sup>1</sup>Research Officer, <sup>2</sup>Professor and H.O.D., Dept of Microbiology, Maratha Mandal's N.G.H. Institute of Dental Sciences and Research Centre, Belgaum, India.

<sup>3</sup>Principal & Professor, Department of Oral Pathology, Maratha Mandal's N.G.H. Institute of Dental Sciences and Research Centre, Belgaum, India.

<sup>4</sup>Professor and H.O.D., Dept of Biotechnology, Gokaraju Rangaraju Institute of Engineering and Technology, Hyderabad, India

## ARTICLE INFO

Received: 24<sup>th</sup> Feb 2016Accepted: 15<sup>th</sup> Mar 2016

\*Corresponding author email:  
saviastar88@yahoo.com

## ABSTRACT

**Aim:** The aim of the present study was to analyze the expression level and localization of Toll-like receptor 2 and Toll-like receptor 4 in gingival samples of healthy and chronic periodontitis subjects by indirect immunofluorescence technique. **Methods:** Gingival tissue samples were obtained from 25 healthy individuals and 25 chronic periodontitis patients. The tissues were processed and the initial characterization was done by H&E staining. Indirect immunofluorescence technique was then performed to detect TLR2 and TLR4. Immunofluorescence images were acquired and quantitative expression of TLRs was analyzed by calculating the percentage of cells showing positive results. **Results:** TLR2 and TLR4 expression in healthy gingival tissues were lower than in the tissues of patients with periodontitis. In patients with periodontitis both TLR2 and TLR4 expression was slightly higher in epithelium as compared to their expression in connective tissue. **Conclusions:** The results suggest that TLR2 and TLR4 in the gingival cells are stimulated by the bacterial products in the oral cavity and participate in the innate immune response against these organisms.

**KEYWORDS:** Chronic Periodontitis, Gingival tissue, Immunofluorescence, TLR2 & TLR4

## INTRODUCTION

The oral cavity is continuously subjected to diseases and disorders caused by oral microorganisms, in particular dental caries and periodontitis. Periodontitis is a chronic inflammation of the gingiva, periodontal tissue destruction and alveolar bone loss caused by the bacteria present in the dental plaque <sup>(1-3)</sup>. Dental plaque contains more than 700 different bacterial species <sup>(4,5)</sup>. Well, we do possess a means of innate defense against these microorganisms. The host defense against these invasive pathogens initiates with its pattern recognition by the immune system <sup>(6)</sup>. Bacteria differ in the composition of their cell walls which act as representative pathogen-associated molecular patterns (PAMPs). In mammals these pathogen associated molecular patterns are recognized specifically by their respective Toll-like receptors (TLRs) on the cell surface of hosts <sup>(7)</sup>.

TLRs are Type I transmembrane proteins with a leucine-rich repeat extracellular domain and a cytoplasmic domain homologous to the mammalian interleukin (IL)-1 receptor <sup>(8-10)</sup>. Ten TLRs have been described in humans and are named TLR1-TLR10 <sup>(11)</sup>. Out of the ten TLRs, TLR2 and TLR4 have been

known to recognize bacterial cell wall components <sup>(12-14)</sup>. TLR2 is the signaling receptor for gram-positive bacterial cell wall components: peptidoglycan (PGN) and lipoteichoic acid (LTA) and TLR4 is the primary signaling receptor for gram negative bacterial cell wall component lipopolysaccharides <sup>(15-17)</sup>.

The periodontal tissue which is a tooth supporting structure consists of gingiva, cementum, periodontal ligament and alveolar bone. The gingiva is constantly exposed to bacterial pathogen-associated molecular patterns. TLR sensing and signaling in periodontal tissue play an important role in the innate immune response and maintain periodontal health <sup>(16)</sup>. The gingival epithelial cells protect the underlining periodontal tissues from microorganisms and other harmful agents. The gingival epithelial cells are multilayered and express TLRs especially TLR2 and TLR4 <sup>(18,19)</sup>. Gingival fibroblasts are the major constituents of periodontal connective tissue. Human gingival fibroblasts constitutively express TLR2 and TLR4 <sup>(18,20,21)</sup>. It was also seen that TLR2 and TLR4 in human gingival fibroblasts were higher in patients with periodontitis than in healthy individuals <sup>(20,21)</sup>.

In the present study, we have made an attempt to study TLR2 and TLR4. We have tried to study the expression and

localization of these TLRs in gingival tissue samples of chronic periodontitis patients and compared them with the gingival tissue samples of healthy individuals. In the gingival tissue samples we have focused on the evaluation of expression of TLR2 and TLR4 on gingival epithelial cells and gingival fibroblasts. To analyze the expression of TLRs we used the immunofluorescent technique because it is more efficient and sensitive method in reference to our earlier study [22]. Immunofluorescence is an antigen-antibody reaction where the antibodies are tagged (labeled) with a fluorescent dye and the antigen-antibody complex is visualized using the ultra-violet (fluorescent) microscope. We used the indirect immunofluorescence format for this study and the quantitative expression of TLRs was analyzed by calculating the percentage of cells showing positive results. This is a first study from India which has analyzed TLR2 and TLR4 using indirect immunofluorescence.

## MATERIAL & METHODOLOGY

### Study design: Analytical study case control study

**Ethical approval:** The study was approved by the Local Ethical Committee at the Maratha Mandal's N.G.H Institute of Dental Sciences and Research Centre, Belgaum, Karnataka, India. Written informed consent was obtained from all study participants before acquiring sample tissues.

**Place of research:** The present study was carried out in the department of Microbiology, Maratha Mandal's N.G. H. Institute of Dental Sciences and Research Center, Belgaum, Karnataka, India.

**Inclusion criteria:** Patients with chronic periodontitis [selected based on the criteria of the American Academy of Periodontology classification [23] included the presence of at least 20 natural teeth, a minimum of 6 periodontal pockets of  $\geq 5$ mm probing depths and clinical attachment loss of  $\geq 3$ mm around the affected teeth. The age range of patients with periodontitis was 20-60 yrs, of both sexes. The inclusion criteria for healthy controls comprised the absence of periodontal diseases having at least 20 natural teeth, age range 20-60 yrs, male or female.

**Exclusion criteria:** The exclusion criteria for both healthy individuals and patients with periodontitis included individuals with any systematic disease/condition, pregnant or lactating women and individuals with a history of dental treatment or drug therapy in the last 3 months prior to the study.

**Sample size:** Total fifty Subjects recruited, which includes 25 healthy individuals without periodontal disease and 25 patients with periodontal disease.

The prevalence of TLR in healthy group is 5-10% assuming maximum prevalence of 10%, to demonstrate prevalence of 50% in period group, using type I error of 0.05, type II error of 0.2 or power of 80% the sample size was calculated using the formula

$$n = \frac{2(Z_{\alpha} + Z_{\beta})^2 pq}{(p_1 - p_2)^2}$$

Where  $Z_{\alpha}$  and  $Z_{\beta}$  are standard normal constants,  $p_1$  - prevalence in healthy samples,  $p_2$  - prevalence in periodontitis samples,  $p = \frac{p_1 + p_2}{2}$ ,  $q = 100 - p$ ,  $Z_{\alpha} : \alpha = 0.05 = 1.96$ ,  $Z_{\beta} : \beta = 0.2 = 0.84$ . Adding the values to the formula the sample size was found out to be 25.

### Methodology:

**Sample Collection:** In patients with chronic periodontitis, gingival tissue samples were collected during periodontal surgeries, which include scaling and root planning. Gingival tissue samples from the 25 healthy controls were obtained during tooth-extraction operations performed for fully impacted, retained wisdom teeth.

**Tissue processing:** Gingival tissue samples were directly collected in cold 95% ethanol (Changshu Yangyuan Chemical, China) [24]. The tissues were trimmed to a thickness of 2-4mm and left for further incubation for 18-24hr in ethanol at 4°C. Tissue samples were then processed by dehydrating in 4 changes of pre-cooled absolute alcohol for 1hr each, transferred to 3 changes of Xylene<sup>TM</sup> (Biolab Diagnostics, Mumbai, India) for 1hr each at 4°C, embedded in paraffin (Fisher Scientific, Bangalore, India) for 4 consecutive baths, 2hr each at 56°C. Tissue sections of 5µm thickness were cut on a microtome (LEICA RM2245) and mounted on APS [(3-Aminopropyl) triethoxysilane] (Sigma, Bangalore, India) coated slide [24].

**Staining:** Initial characterization of gingival tissue samples was done by performing hematoxylin (NICE, Kerala, India) and eosin (SDFCL, Mumbai, India) staining on all the specimens [25].

**Immunofluorescence:** An indirect immunofluorescence technique was performed to detect TLR2 and TLR4 on mounted sections of 5µm thickness. Tissue sections were incubated for 45 minutes at room temperature with TLR2 or TLR4 primary antibody (Purified Anti-Human, BioLegend, San Diego); at least two slides per sample were tested for each antibody. We used Mouse monoclonal antibody against human TLR2 and TLR4, diluted 1:50 in sterile Phosphate Buffered Saline (PBS). At the end of incubation, the slides were washed with PBS-T [50 ml PBS + 25µl Tween 20<sup>RM</sup> (Himedia, Mumbai, India)] for 5minutes for about 2-3 times. Tissue sections were then incubated for one hour in secondary antibody conjugated with FITC (Fluorescein isothiocyanate, Goat Anti-Mouse IgG, Imgenex, India), 1:200 dilution, blocked with 5% goat serum in PBS-T for 5-10 minutes then washed with PBS-T for 5 minutes for about 2-3 times and mounted in DPX mountant (Biolab Diagnostics, India) [26].

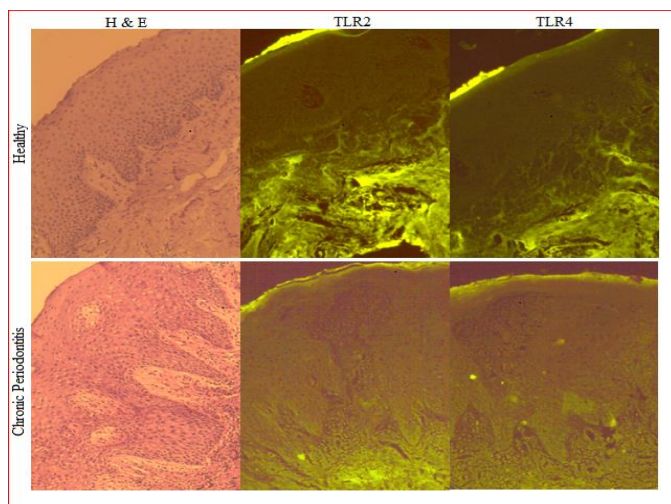
Immunofluorescence images were acquired using a fluorescent (UV) microscope (Olympus BX41), with photographic attachment. At least 3-4 representative images were captured and analyzed per slide.

**Statistical analysis:** The results are presented as mean  $\pm$  SD (Standard Deviation), the concentration of TLR 2 and TLR 4 was compared between the chronic periodontitis and periodontally healthy groups using the *t*-test and the Mann-Whitney U-test and  $p < 0.05$  was considered statically significant.

## RESULTS

A total of fifty gingival tissue specimens were studied. Twenty five from healthy individuals and another twenty five from patients with chronic periodontitis. Each tissue was first studied by hematoxylin and eosin staining for histopathological characteristics. Indirect immunofluorescence was done for expression of TLR2 and TLR 4, in gingival epithelial cells and gingival connective tissue cells. A semi-quantitative analysis was carried out based on the number of cells that took up the specific stain and the positivity was expressed in terms of percentage.

**Histopathological characteristics:** Sections of tissues were stained with hematoxylin and eosin to determine the histological characteristics. Healthy gingival tissues showed a typical keratinized stratified squamous epithelium with minimal inflammatory infiltrates in them. In the tissues of patients with chronic periodontitis, keratinized stratified squamous epithelium showed changes such as edema and exocytosis mainly due to the effect of chronic inflammatory infiltrate found predominantly in lymphocytes and plasma cells (Figure 1).



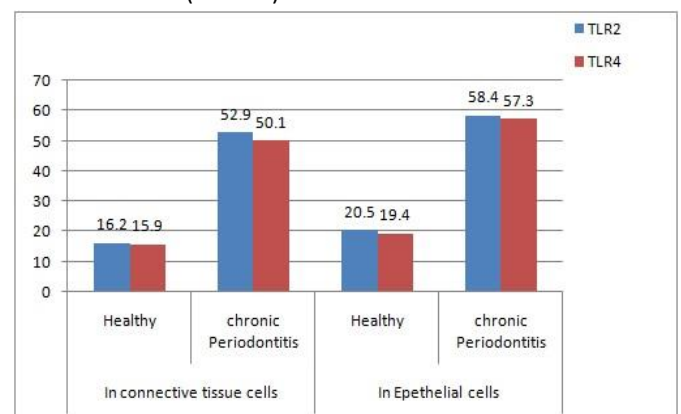
**Figure 1.** Immunolocalization of Toll-like receptor 2 and Toll-like receptor 4 in gingival tissue samples from healthy controls and patients with chronic periodontitis. Respective images of Hematoxylin and Eosin (H&E), stained tissue sections are shown in the first left panel.

**Expression and localization of TLR2 in gingival tissue:** TLR2 expressions in healthy gingival tissues were lower than in the tissues of patients with periodontitis. In patients with periodontitis, TLR2 expressions were slightly higher in epithelium as compared to their expression in connective tissue (Figure 1).

**Expression and localization of TLR4 in gingival tissue:** TLR4 expressions in healthy gingival tissues were also lower than in the tissues of patients with periodontitis. In patients with periodontitis TLR4 expressions were slightly higher in epithelium as compared to their expression in connective tissue (Figure 1).

**Analysis of TLR2 expression in gingival tissue:** TLR2 expression in the epithelial cell of periodontitis patients were 58.4% ( $\pm 19.82$ ) when compared to their expression in epithelial cells of healthy individuals which were 20.5% ( $\pm 3.56$ ). This difference was highly significant with a *p*-value of  $< 0.001$ . TLR2 expression in the connective tissue cells of periodontitis patients were significantly higher with a positivity rate of 52.9% ( $\pm 16.61$ ) when compared to their expression in the connective cells of healthy individuals which were 16.2% ( $\pm 3.92$ ). This difference was also highly significant with a *p*-value of  $< 0.001$  (Table1).

**Analysis of TLR4 expression in gingival tissue:** TLR4 expression in the epithelial cell of periodontitis patients were 57.3% ( $\pm 21.16$ ) when compared to their expression in epithelial cells of healthy individuals which were 19.4% ( $\pm 8.82$ ). This difference was highly significant with a *p*-value of  $< 0.001$ . TLR4 expression in the connective tissue cells of periodontitis patients were significantly higher with a positivity rate of 50.1% ( $\pm 19.25$ ) when compared to their expression in the connective cells of healthy individuals which were 15.9% ( $\pm 4.31$ ). This difference was also highly significant with a *p*-value of  $< 0.001$  (Table 1).



**Figure 2.** Comparison of TLR 2 and TLR4 within each group

**Table 1. Comparison of TLR 2, TLR 4 in Epithelium and Connective tissue cells of Healthy and Chronic periodontitis**

TLRs	Tissue	Grouping		t-test	p-value	Mann–Whitney U test	p-value
		Healthy	Chronic Periodontitis				
TLR2	Epithelial cells	20.5±3.56	58.4±19.82	9.419	<b>p-value</b>	6.199	<0.001
	Connective tissue cells	16.2±3.92	52.9±16.61	10.77		6.028	<0.001
TLR4	Epithelial cells	19.4±5.82	57.3±21.16	8.655	<0.001	6.196	<0.001
	Connective tissue cells	15.9±4.31	50.1±19.25	8.659	<0.001	6.061	<0.001

Data expressed as **Mean±SD, <0.001 significant**

## DISCUSSION

Periodontal disease as mentioned earlier is a chronic bacterial infection. Dental plaque biofilms have been well recognized as etiological agents. The disease initiation and progression result from the host response to plaque bacteria which further leads to gingival inflammation and tissue destruction. In other words, TLRs on microbial recognition activate signaling pathways that are critical for induction of the immune response to the given microbial challenge as periodontal pathology is initiated by gram positive organisms and progressed by gram-negative organisms. TLR4 is the dominant receptor for the gram-negative lipopolysaccharides, whereas TLR2 mediates signals from gram-positive bacterial components including lipoteichoic acid, peptidoglycan and lipoprotein/lipopeptides.

In the present study, we analyzed the expression of TLR2 and TLR4 in gingival tissues from healthy individuals and from chronic periodontitis patients using immunofluorescence. In the gingival tissues, we analyzed TLR expression in gingival epithelial cells and gingival connective tissue cells. TLR2 and TLR4 expression profiles have been exhaustively examined in several earlier studies. For example, Hatakeyama et al. in 2003 showed that TLR2 and TLR4 were found to be expressed in healthy human gingival tissues [27]. In another study Ren et al. in 2004 detected only weak expression of TLR2 and no TLR4 in healthy gingival tissue [28]. Our results proved that both TLR2 and TLR4 were expressed in healthy and chronic periodontitis patients. Another study by Mori et al. in 2003 investigated the expression of TLR2 and TLR4 in human periodontal diseases and showed higher TLR2 positive cells in the mild group and higher TLR4 positive cells in severe gingivitis [12]. In a 2006 study by Sarah et al. showed significantly elevated TLR2 and TLR4 in tissues of patients with gingivitis and chronic periodontitis compared to controls [29]. Similarly, Uehara et al. in 2007 showed that human gingival fibroblasts expressed TLR2 and TLR4 which turned out to be significantly elevated in inflammation [30]. Also in a report by Beklen et al. in 2008 where the immunohistochemical localization of TLR1-10 was studied, consistently higher TLR expression was found (particularly in the connective tissue) within the periodontal group compared with the healthy group [13]. In 2011 Rojo-Botello conducted immunofluorescent studies and proved

that expression levels of TLR2 and TLR4 were higher in all periodontal patients than in healthy individuals [14], which coincided with our results where we found TLR2 and TLR4 expression in healthy individuals was lower than in chronic periodontitis patients. Sugawara et al. in 2006 proved that compared to healthy controls increased expression of TLR2 and TLR4 by inflamed oral epithelium located at cell borders was seen [6]. In our study we saw that in healthy individuals, TLR2 and TLR4 expression was slightly higher in epithelial cells than in connective tissue cells. Similarly, in patients with periodontitis, TLR2 and TLR4 expression was higher in epithelial cells than in connective tissue cells. The gingival epithelial cells, are in constant contact with the oral microorganisms especially bacteria and act as the first layer of defense, whereas the connective tissue which is primarily composed of fibroblasts are exposed later (Figure 2). This may be the reason why the epithelial cells expressed higher levels of TLR2 and TLR4 than the connective tissue cells of all the groups. This data was also proved by some earlier researchers like Rojo-Botello et al., 2012 [14]; and Beklen et al., 2008 [13].

## CONCLUSION

Hence from all these findings it can be concluded that TLR2 and TLR4 is expressed on gingival tissues and recognize different bacterial cell wall components. Further investigations on TLR2 and TLR4 signaling are necessary for better understanding of periodontal health and diseases.

## ACKNOWLEDGMENT

We thank Mr Mayur Waddinar and Mrs Geeta Patil for their technical help. We also thank Mr Mallapur (Lecturer in Statistics, Department of Community Medicine from J. N. Medical College, Belgaum) for statistics.

## REFERENCES

1. Mariotti A. Dental plaque-induced gingival diseases. *Ann Periodontol.* 1999; 4: 7-19.
2. Haffajee AD, Socransky SS. Microbial etiological agents of destructive periodontal diseases. *Periodontol.* 2000; 5: 78–111.
3. Moore WEC and Moore LVH. The bacteria of periodontal diseases. *Periodontol* 2000. 1994; 5: 66-77.
4. Aas JA, Paster BJ, Stokes LN, Olsen I, Dewhirst FE. Defining the normal bacterial flora of the oral cavity. *J Clin Microbiol.* 2005; 43: 5721-32.



5. Paster BJ, Boches SK, Galvin JL, Ericson RE, Lau CN, Levanos VA, et al. Bacterial diversity in human subgingival plaque. *J Bacteriol.* 2001; 183: 3770-83.
6. Sugawara Y, Uehara A, Fujimoto Y, Kusumoto S, Fukase K, Shibata K, et al. Toll-like Receptors, NOD1, and NOD2 in Oral Epithelial Cells. *J Dent Res.* 2006; 85: 524-9.
7. Hans M and Hans VM. Toll-like receptors and their dual role in periodontitis: a review. *J Oral Sci.* 2011; 53(3):263-71.
8. Medzhitov R, Preston-Hurlburt P, Janeway CA Jr. A human homologue of the *Drosophila* Toll protein signals activation of adaptive immunity. *Nature.* 1997; 388: 394-7.
9. Belvin, MP, and Anderson KV. A conserved signaling pathway: the *Drosophila* toll-dorsal pathway. *Annu. Rev. Cell Dev. Biol.* 1996; 12: 393-416.
10. Hoffmann JA, Kafatos FC, Janeway CA and Ezekowitz RA. Phylogenetic perspectives in innate immunity. *Science.* 1999; 284:1313-8.
11. Beutler B. Inferences, questions and possibilities in Toll like receptor signaling. *Nature.* 2004; 430: 257-63.
12. Mori Y, Yoshimura A, Ukai T, Lien E, Espevik T, Hara Y. Immunohistochemical localization of toll-like receptors 2 and 4 in gingival tissue from patients with periodontitis. *Oral Microbiol Immunol.* 2003; 18:54-58.
13. Beklen A, Hukkanen M, Richardson R, Kontinen YT. Immunohistochemical localization of toll-like receptors 1–10 in periodontitis. *Oral Microbiol Immunol.* 2008; 23:425-31.
14. Rojo-Botello NR, Garcí'a-Hernández AL, Moreno-Fierros L. Expression of toll-like receptors 2, 4 and 9 is increased in gingival tissue from patients with type 2 diabetes and chronic periodontitis. *J Periodont Res.* 2012; 47: 62–73.
15. Takeuchi O, Hoshino K, Kawai T, Sanjo H, Takada H, Ogawa T, et al. Differential Roles of TLR2 and TLR4 in Recognition of Gram-Negative and Gram-Positive Bacterial Cell Wall Components. *Immunity.* 1999; 11: 443-51.
16. Mahanonda R and Pichyangkul S. Toll-like receptors and their role in periodontal health and disease. *Periodontol* 2000. 2007; 43: 41-55.
17. Akira S, Uematsu S, Takeuchi O. Pathogen recognition and innate immunity. *Cell.* 2006; 124:783-801.
18. Nonnenmacher C, Dalpke A, Zimmermann S, Flores-de-Jacoby L, Mutters R, Heeg K. DNA from Periodontopathogenic Bacteria Is Immunostimulatory for Mouse and Human Immune Cells. *Infect Immun.* 2003; 71(2): 850-6.
19. Kawai T, Takeuchi O, Fujita T, Inoue J, Mühlradt PF, Sato S, et al. Lipopolysaccharide Stimulates the MyD88-Independent Pathway and Results in Activation of IFN-Regulatory Factor 3 and the Expression of a Subset of Lipopolysaccharide-Inducible Genes. *J Immunol.* 2001; 167: 5887-94.
20. Tabeta K, Yamazaki K, Akashi S, Miyake K, Kumada H, Umemoto T, et al. Toll-like receptors confer responsiveness to lipopolysaccharide from *Porphyromonas gingivalis* in human gingival fibroblasts. *Infect Immun.* 2000; 68: 3731-5.
21. Wang PL, Ohura K, Fujii T, Oido M, Kowashi Y, Kikuchi M, et al. DNA microarray analysis of human gingival fibroblasts from healthy and inflammatory gingival tissues. *Biochem Biophys Res Commun.* 2003; 305: 970-3.
22. D'Souza RS, Bhat KG, Sailaja D, Babji DV, Bandiwadekar TK, Katgalkar RM. Analysis of Expression and Localization of TLR-2 by Immunofluorescent Technique in Healthy and Inflamed Oral Tissues. *JCDR.* 2013; 7(12):2780-3
23. Armitage GC. Development of a classification system for periodontal diseases and conditions. *Ann Periodontol.* 1999; 4(1):1-6.
24. Johnson GD and Dorling J. Immunofluorescence and immunoperoxidase techniques. In: R.A. Thompson ed. *Techniques in Clinical Immunology*, 2<sup>nd</sup> edition. Blackwell Scientific Publications, London. 1981: 106-137.
25. Bancroft JD, Gamble M. *Theory and Practice of Histological Techniques*, 5<sup>th</sup> ed., Churchill Livingstone, Edinburgh. 2002: 125-138.
26. Gao Y, Hubbert CC, Lu J, Lee YS, Joo-Yong, Yao TP. Histone deacetylase 6 regulates growth factor-induced actin remodeling and endocytosis. *Mol Cellular Biol.* 2007; 8637-47.
27. Hatakeyama J, Tamai R, Sugiyama A, Akashi S, Sugawara S, Takada H. Contrasting responses of human gingival and periodontal ligament fibroblasts to bacterial cell-surface components through the CD14/Toll-like receptor system. *Oral Microbiol Immunol.* 2003; 18(1):14-23.
28. Ren L, Jin L, Leung WK. Local expression of lipopolysaccharide-binding protein in human gingival tissues. *J Periodont Res.* 2004; 39: 242-8.
29. Sarah SM, Tamilselva S, Kamatchiammal S, Suresh R. Expression of Toll-like receptor 2 and 4 in gingivitis and chronic periodontitis. *Ind J Dent Res.* 2006; 17(3): 114-6.
30. Uehara A and Takada H. Functional TLRs and NODs in Human Gingival Fibroblasts. *J Dent Res.* 2007; 86(3):249-54.